



HEALTH
KwaZulu-Natal

VERTROULIK
CONFIDENTIAL

ANNEX

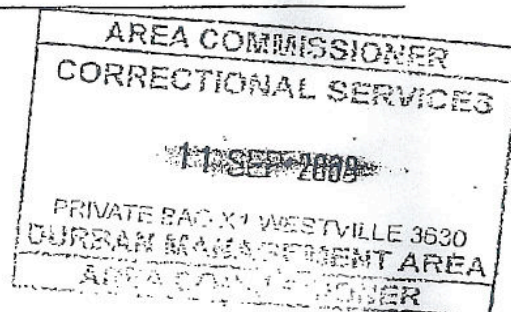
800 Bellair Road, Mayville, 4091
Private Bag X03, Mayville, 4058
Tel: 031 - 240 1000
Email: @ialch.co.za
www.kznhealth.gov.za

THE HEAD
Medium B
Westville Correctional Services
Durban

Dear Mr Marais,

Re: SCHABIR SHAIK

Patient number : KZ00132232



Mr Shaik was diagnosed with systemic hypertension in 2001 at the age of 44 years. He had been on medication and under the care of a private specialist physician since that time. Following his incarceration, he was admitted to St. Augustine's Hospital in 2006 where investigations showed him to have hypertensive end organ damage with retinopathy, hypertensive heart disease with left ventricular hypertrophy and diastolic dysfunction; as well as non-occlusive coronary artery disease, peripheral vascular disease and dyslipidaemia. Throughout his hospitalization at St. Augustine's and whilst under the care of several specialists, including experts from outside KZN who were consulted regarding his management, his blood pressure remained persistently elevated despite the incremental addition of multiple anti-hypertensive medications. Additionally, he has a strong family history of coronary artery disease and hypertension (parents had fatal myocardial infarcts and a brother underwent coronary artery bypass surgery; both parents and two siblings are hypertensive).

The cardiology team at Inkosi Albert Luthuli Hospital was initially consulted in April 2007. At the time, he was on thirteen different medicines, eight of which were for control of the hypertension. Blood pressure control remained problematic and he was extensively investigated for a secondary cause. The only positive yield was a low serum renin level. The end organ damage as previously documented, was again confirmed. Appropriate adjustments were made to his medication and the doses were increased to maximal recommended levels, but medication remained ineffectual. During his hospitalization, his blood pressure has been strictly monitored, including by invasive means, but therapeutic targets for optimal control have not been reached. The blood pressure recordings were done in the resting state and when recorded during moderate exertion under controlled circumstances, it reached exceedingly high levels. He has continued to have symptoms related to poor pressure control and of concern there has been progression in the severity of the end organ damage such that the retinopathy has been assessed by the ophthalmologist to now be of grade IV severity. His most recent admission to the intensive care unit was precipitated by a severe surge in blood pressure during the

early hours of the morning when the ECG showed changes compatible with an acute myocardial injury pattern, which, if not acted upon urgently, may have led to a heart attack.

Aside from his psychiatric medication (see psychiatrist's report), Mr Shaik is currently on the following hypertensive and cardiac medicines:

Hydrochlorothiazide 25 mg daily

Furosemide 40 mg bd

Eplerenone 100 mg daily

Bisoprolol 10 mg daily

Doxazosin 8 mg daily

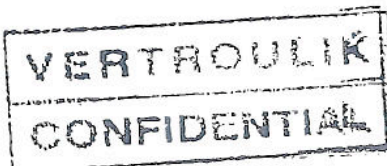Nifedipine XL 90 daily

Valsartan 320 mg bd

Minoxidil 20 mg bd

Isosorbide mononitrate 20 mg bd


Atorvastatin 10 mg daily



Mr Shaik frequently uses analgesics in order to obtain some relief from the severe bouts of headaches related to poor blood pressure control. The analgesic that affords him best relief is Myprodol but I have discontinued it because of the non-steroidal content that may contribute to poor BP control. For the same reasons, Aspirin has also been withdrawn. He was recently commenced on yet another anti-hypertensive agent, Physiotens 0.4 mg daily that is a centrally acting agent, but this had to be discontinued because it aggravated his depressive symptoms.

Despite our best efforts, Mr Shaik's pressure remains refractory to medication. The target organ damage, including progression in the severity of organ damage, has been objectively documented. He remains at risk for a stroke, heart attack and blindness. Perhaps psychological factors related to his incarceration have contributed to his physical ailments, especially the inability to achieve blood pressure control. The psychiatric medication that he has been on since 2006 has not led to any improvement in his physical condition. He has had a lengthy stay under specialist care, without effect. Currently he is undergoing psychotherapy/counselling by the psychologist as a final resort to obtain some improvement in blood pressure control. We cannot keep him in hospital indefinitely and since the prison authorities are reluctant to manage him at the prison hospital, where conditions are suboptimal, we recommend that he be considered for medical parole.

For details on medical reports, please refer to previous correspondence to the Dept. of Correctional Services.


Professor DP Naidoo
Chief Specialist/ Head
Dept. of Cardiology
Nelson R Mandela School of Medicine,
University of Kwa Zulu Natal


Dr S Khan
Principal Specialist in Cardiology
Nelson R Mandela School of Medicine,
University Of Kwa Zulu Natal